



PATIENT

Daisy Clark

SPECIES

Canine

BREED

Jack Russell Terrier

Mix

SEX

Female SPayed

AGE

14.4 years

WEIGHT

11lbs

INTERPRETED BY

Maggie Machen Lamy,
DVM, DACVIM
(Cardiology)

IMAGING PERFORMED BY

Amanda Crook, SDEP

HOSPITAL NAME

River Edge Pet Medical
Center

REFERRING VET

Dr. Todd

INVOICE

46504

DATE

1/20/26

PRESENTING CLINICAL SIGNS

History: Recheck echo. BP: 110, 110, 105, 92, 95mmHg. CXR showed significant cardiomegaly with LA enlargement. Abnormal labs: Monocytosis 1.19k/ul, Azotemia, Hypophosphatemia.
-Current medications: Hydrocodone, Furosemide, Pimobendan.
-Pertinent previous echo findings (9/2024 MML): CVD severe, stage C. Severe MR, severe LAE, mild LVE, mild TR, mild to moderate PH: 3.5m/s. LA: 3.2, LV: 3.8.

RADIOGRAPHIC FINDINGS *NOTE: Images submitted for supplemental cardiac information only.
Cardiomegaly. No obvious evidence of CHF.

ELECTROCARDIOGRAPHIC FINDINGS

A six lead ECG is available at 50mm/s; 5mm/mV. The average heart rate is 166bpm. The rhythm is sinus in origin, with a p for every QRS complex and vice versa. The P wave morphology is positive with a normal dimension. Normal PR. The QRS morphology is positive with normal dimension. MEA is normal. No ectopic beats, pauses or dysrhythmias observed.
ECG diagnosis: Normal sinus rhythm.

ECHOCARDIOGRAM FINDINGS

2D, m-mode, color flow and doppler imaging is available. Diffuse thickening of mitral valve leaflets with prolapse into the left atrial lumen. Severe eccentric mitral regurgitation with severe left atrial dilation. Normal MR velocity. Mild LV dilation with hyperdynamic myocardial function. The tricuspid valve appears thickened with septal prolapse and mild TR. Moderately elevated velocity. Normal right atrial and ventricular diameter and morphology. The pulmonic and aortic valves are normal in morphology and mobility. Normal aortic and pulmonic outflow velocities with laminar flow. No AI/PI. No pericardial or pleural effusion noted. No obvious cardiac masses. Premature beats suspected.

CARDIAC CHART

CANINE CARDIAC PARAMETERS	MR VMAX (m/s)	TR VMAX (m/s)	LA/AO (Boon method)	LA/AO (Heart Base; Swe)	FS (%)	EF (%)	EPSS (cm)
NORMAL PARAMETER	4.5-5.5	<2.7	1.3	<1.6	28-40	40-100	<0.6
PATIENT	5.1	4.0	NM	2.4	56	88	NM
CANINE CARDIAC PARAMETERS	HR (BPM)	AV VMAX (m/s)	PV MAX (m/s)	BODY WEIGHT (kg)	LA 2D short axis Base view (cm)	LVIDd Avg; 2D and m-mode short axis (cm)	LVIDs Avg; 2D and m-mode short axis (cm)
NORMAL PARAMETER	50-100	0.7-1.7	0.7-1.6	BELOW	BELOW	BELOW	BELOW
PATIENT	NM	1.5	0.75	5.0	3.4	3.6	1.6
*Normal chamber parameters expressed as a mean value (SD)				3	1.27 (5.3)	2.46 (2.46)	1.36 (5.5)
BODY WEIGHT DEPENDENT PARAMETERS				5	1.40 (4.5)	2.74 (5.2)	1.60 (4.7)
*Note: All measurements based upon multi-modal images and methods. An average value is reported.				10	1.50 (3.8)	3.27 (3.5)	2.06 (3.1)
				15	1.83 (2.0)	3.71 (2.4)	2.43 (2.1)
				20	2.02 (1.9)	4.14 (2.2)	2.80 (2.0)
				25	2.18 (2.4)	4.48 (2.9)	3.10 (2.5)
				30	2.33 (3.3)	4.83 (3.9)	3.39 (3.4)
				35	2.48 (4.3)	5.17 (5.0)	3.69 (4.5)
				40	2.62 (5.2)	5.48 (6.1)	3.96 (5.4)
				50	2.88 (7.1)	6.07 (8.3)	4.46 (7.4)

Adapted from June Boon, Veterinary Echocardiography, 1998
Rishniw M and Hollis NE, J Vet Intern Med 2000; 14:429-435
Hansson et al, Vet Rad and Ultrasound 2002
Bonagura et al. Echocardiography: principles of interpretation, Vet Clin North Am 15:1177, 1995



PATIENT

Daisy Clark

SPECIES

Canine

BREED

Jack Russell Terrier
Mix

SEX

Female SPayed

AGE

14.4 years

WEIGHT

11lbs

INTERPRETED BY

Maggie Machen Lamy,
DVM, DACVIM
(Cardiology)

IMAGING PERFORMED BY

Amanda Crook, SDEP

HOSPITAL NAME

River Edge Pet Medical
Center

REFERRING VET

Dr. Todd

INVOICE

46504

DATE

1/20/26

INTERPRETATION OF THE FINDINGS & FURTHER RECOMMENDATIONS

Compared to the prior evaluation, findings are similar yet severe. Severe mitral and mild tricuspid regurgitation are unchanged with stable four chamber dimensions. Pulmonary pressures have increased slightly compared to the prior evaluation. In the absence of reported syncope, simple monitoring is advised. No additional issues are identified.

The ECG appears normal with a normal sinus rhythm. Premature beats are suspected during the study that were potentially not captured, as these are not documented on the ECG. If these are a persistent find on exam, a longer tracing or holter monitor may be indicated.

Given these findings, full cardiac medications should be continued going forward with consistent dosing as able. Monitoring of sleeping respiratory rates will be paramount to screen for congestive heart failure at home. Cough suppression to improve QOL can also be considered (hydrocodone, 0.2-0.4mg/kg up to q4-6h PRN) for any residual mechanical cough in the face of normal sleeping respiratory rates. The average survival time of canine patients with active pulmonary edema is 8-9 months on medications, however they generally are able to maintain a good quality of life for that period. Patient will always be at risk for recurrent CHF, development of arrhythmias/LA tear, syncope and/or sudden death in the future.

Omega fatty acid supplementation and mild salt restriction may also be of some long-term benefit. Monitor for acute progression of the cough, labored breathing, exercise intolerance or collapse episodes in the future.

Elective anesthesia is not advised.

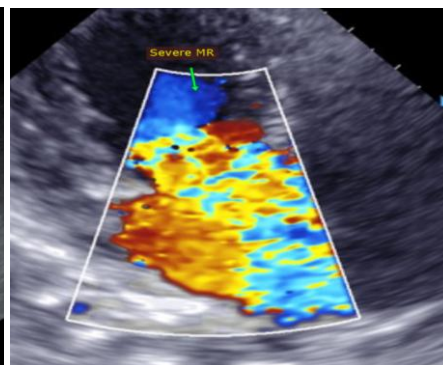
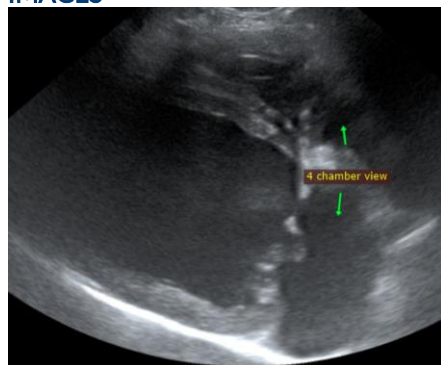
PLAN

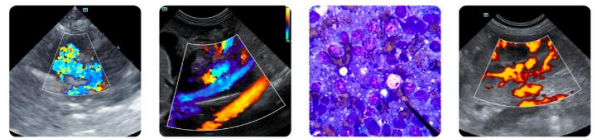
If arrhythmias are noted in the future, a repeat ECG or ideally a holter monitor should be considered. Continue Pimobendan 0.3mg/kg PO q12h. Continue Furosemide 1-2mg/kg PO q12h. Institute Spironolactone 1-2mg/kg PO q12h.

Monitor SRRs at home. Monitor renal values and BP every 3-4 months while on diuretics. Consider hydrocodone if needed for QOL.

Recommend conservative monitoring with a recheck echocardiogram in 6 months, sooner if any development of associated clinical signs occurs in the interim.

IMAGES





PATIENT

Daisy Clark

SPECIES

Canine

BREED

Jack Russell Terrier
Mix

SEX

Female SPayed

AGE

14.4 years

WEIGHT

11lbs

INTERPRETED BY

Maggie Machen Lamy,
DVM, DACVIM
(Cardiology)

IMAGING PERFORMED BY

Amanda Crook, SDEP

HOSPITAL NAME

River Edge Pet Medical
Center

REFERRING VET

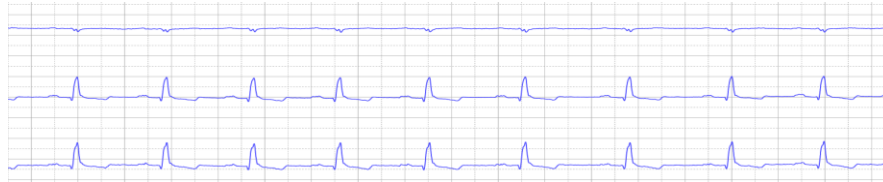
Dr. Todd

INVOICE

46504

DATE

1/20/26



The information and recommendations provided are based on the images presented by the referring veterinarian. No evaluation can be communicated regarding pathology that was not visible in the image/video clips provided.

Thank you for this referral. This report was generated using transcription software, and minor dictation errors may be present. If the clinical or image interpretation does not parallel your findings or if I can be of any further assistance, please contact me.

Maggie Machen Lamy, DVM
Diplomate of the American College of Veterinary Internal Medicine (Cardiology)
info@sonopath.com